

LETTERS TO THE EDITOR

Brown-Séquard syndrome in a patient with spondyloarthritis after COVID-19 vaccine: a challenging differential diagnosis

Costa R^{1,2}, Soares C^{1,2}, Vaz C³, Bernardes M³, Tavares M⁴, Abreu P^{1,2}

Transverse myelitis (TM) is a rare disorder with multiple etiologies, including infectious, parainfectious or paraneoplastic causes, induced by drugs/toxins and associated with systemic autoimmune disorders or acquired demyelinating diseases¹. Many vaccines are associated with TM, including both adenovirus-vector-

ized and mRNA COVID-19 vaccines. Myelitis is also a known complication of COVID-19 disease².

In January 2021, a 41-year-old woman with non-radiographic axial and peripheral spondyloarthritis (SpA), diagnosed in 2000, HLA-B27 positive, taking adalimumab since 2010 (40mg every three weeks) with no side effects, started an acute neck pain followed by motor impairment of the right limbs and decreased thermal sensibility on the left leg. Her complaints started seven days after the administration of the first dose of COVID-19 nucleoside-modified mRNA vaccine (Comirnaty). The last dose of adalimumab was 47 days before clinical onset due to scheduled vaccination.

She presented a right Brown-Séquard syndrome (right-sided hemiparesis, right-sided proprioceptive deficit and left-sided pain and temperature diminished sensation with sensory level at C3). Anti-nuclear an-

¹ Department of Neurology, Centro Hospitalar Universitário de São João, Porto, Portugal; ² Department of Clinical Neurosciences and Mental Health, Faculty of Medicine of University of Porto, Porto, Portugal; ³ Department of Rheumatology, Centro Hospitalar Universitário de São João, Porto, Portugal; Department of Medicine/Rheumatology, Faculty of Medicine of University of Porto, Porto, Portugal; ⁴ Department of Infectious Diseases, Centro Hospitalar Universitário de São João, Porto, Portugal; EPI Unit - Instituto de Saúde Pública, University of Porto, Porto, Port

Correspondence to: Rafaela Costa
E-mail: rafaelasacosta@gmail.com

Submitted: 29/11/2021

Accepted: 18/03/2022

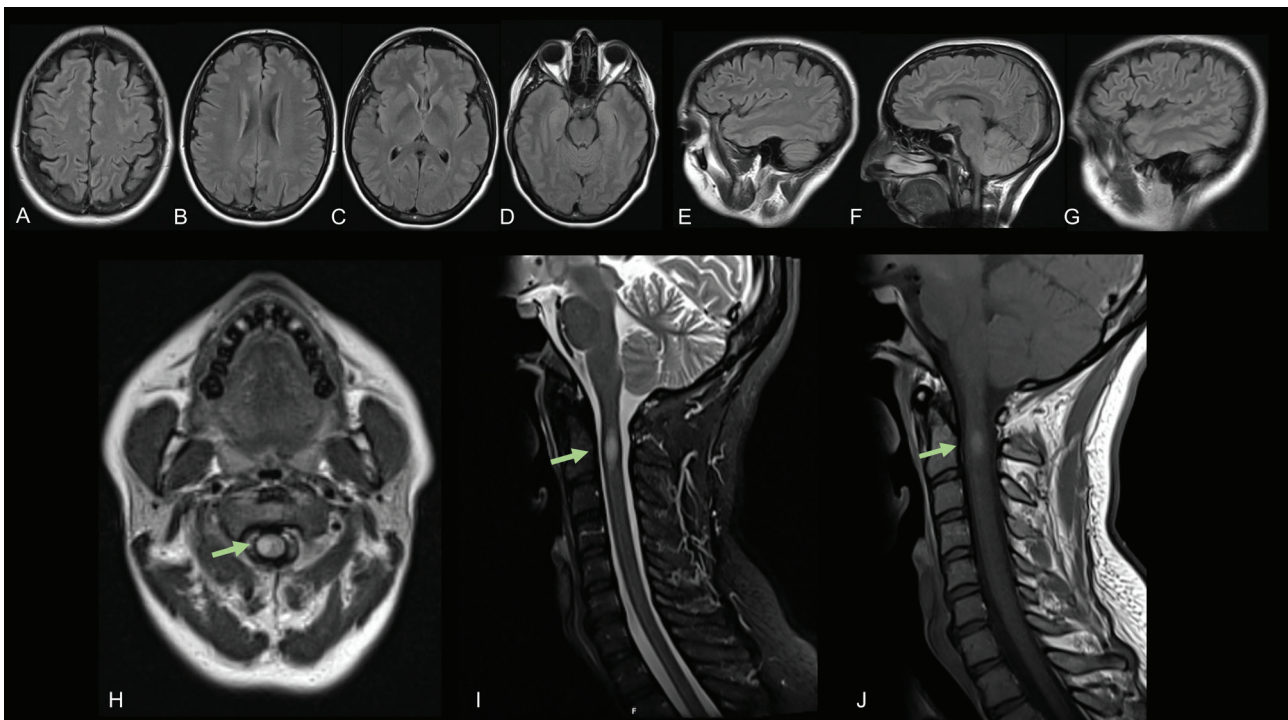


Figure 1. (A-D) Axial and (E-G) sagittal T2-weighted fluid-attenuated inversion recovery (FLAIR) images depicting sparse and unspecific small round hyperintensities. (H) Axial T2-weighted and (I) sagittal T2-weighted showing a partial myelitis encompassing right lateral funiculi at C2 level (green arrows). (J) Sagittal T1-weighted sequence showing central gadolinium enhancement.

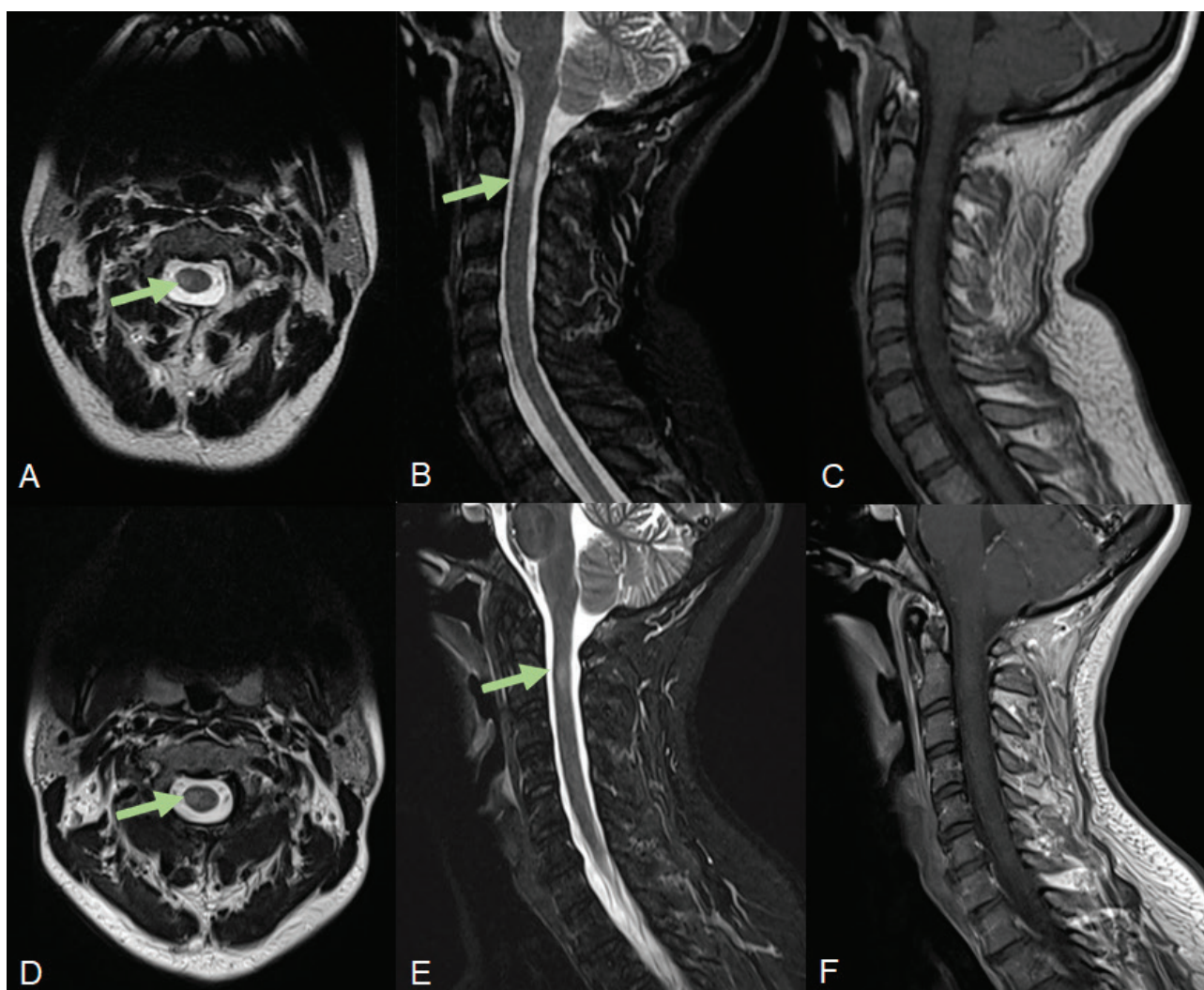


Figure 2. (A), (B), (C) – Neuroaxis MRI at 15-week follow-up; (D), (E), (F) – Neuroaxis MRI at 31-week follow-up; (A), (D) – axial and (B), (E) – sagittal T2-weighted showing progressive resolution of the previously described lesion. (C), (F) – Sagittal T1-weighted sequence with gadolinium, at 15- and 31-weeks MRI follow-up, respectively, without gadolinium enhancement.

tibodies were positive (>1:1000), but the remaining immune study [enzyme-conversion angiotensin (ECA), anti-dsDNA, rheumatoid factor, extractable nuclear antigens, anticardiolipin and onconeural antibodies] was normal/negative. Cerebrospinal fluid (CSF) study was unremarkable including ECA, oligoclonal bands (OCB) and IgG index. Serum OCB, myelin oligodendrocyte glycoprotein and aquaporin-4 antibodies assessed by fixed cell-based assay were also negative. High resolution thoracic Computerized tomography (CT) scan showed no abnormalities. Insipient inflammatory signs of the sacroiliac joint were found on Magnetic Resonance Imaging (MRI). Neuroaxis MRI depicted unspecific supratentorial small round hyperintensities and an acute inflammatory lesion at C2 level (Figure 1).

The patient was started on methylprednisolone (1g/day for five days), with improvement in sensory-motor

deficits. Tumor Necrosis Factor alpha (TNF-) inhibitors are contraindicated after a demyelinating event³, thus adalimumab was switched to secukinumab. The benefits and potential risks of vaccination were explained to the patient and an administration of a vaccine with a different mechanism of action was suggested^{4,5}, however the patient decided not to take it. There was resolution of neurological symptoms, and the patient had no recurrency of neurological deficits since then. Brain and spine MRI 15 weeks and 31 weeks after, showed progressive regression of the spinal lesion, with no other new abnormalities being detected (Figure 2).

Three scenarios should be discussed in this case. Myelitis could be a manifestation of a primary central nervous system (CNS) demyelinating disorder or a secondary manifestation of the underlying rheumatologic disease. The first seems unlikely, since serum and CSF

immune studies were unremarkable and no evidence of dissemination in space or time was found, even at follow-up MRI⁶.

A secondary CNS manifestation of her rheumatologic disorder cannot be ruled out, but it seems unlikely. Since, and despite, the interruption of adalimumab, no clinical worsening was noticed, and CNS involvement is an uncommon extra-articular complication of SpA. However, there are few reports in the literature of association between TM and SpA, namely ankylosing spondylitis, and psoriatic arthritis. This clinical manifestation occurs mainly in patients with long-standing disease⁷.

Alternatively, the widespread use of TNF- inhibitors led to a growing number of demyelinating events reported in literature^{8,9}. Nevertheless, adalimumab was taken 47 days before myelitis clinical onset and its half-life ranges from 10-20 days across studies¹⁰.

Finally, vaccine might have triggered or exacerbated an immune response. The association between SARS-CoV2 vaccines and TM was firstly reported with the adenovirus-vectored vaccine² and more with mRNA vaccines^{11,12}.

We report a case of TM with a challenging etiological diagnosis and management. The patient maintains follow-up by Neurology and Rheumatology, including periodic neuroaxis imaging.

REFERENCES

- Beh SC, Greenberg BM, Frohman T, Frohman EM. Transverse Myelitis. *Neurologic Clinics*. 2013;31(1):79-138.
- Román GC, Gracia F, Torres A, Palacios A, Gracia K, Harris D. Acute Transverse Myelitis (ATM): Clinical Review of 43 Patients With COVID-19-Associated ATM and 3 Post-Vaccination ATM Serious Adverse Events With the ChAdOx1 nCoV-19 Vaccine (AZD1222). *Frontiers in immunology*. 2021;12:653786.
- Ward MM, Deodhar A, Gensler LS, Dubreuil M, Yu D, Khan MA, et al. 2019 Update of the American College of Rheumatology/Spondylitis Association of America/Spondyloarthritis Research and Treatment Network Recommendations for the Treatment of Ankylosing Spondylitis and Nonradiographic Axial Spondyloarthritis. *Arthritis Rheumatol*. 2019 Oct;71(10):1599-1613. doi: 10.1002/art.41042. Epub 2019 Aug 22. PMID: 31436036; PMCID: PMC6764882.
- Kroger A, Bahta L, Hunter P. Updated February 15, 2022. General Best Practice Guidelines for Immunization. Centers for Disease Control and Prevention (CDC). <https://www.cdc.gov/vaccines/hcp/acip-recs/general-recs/index.html>
- Donofrio PD. Guillain-Barré Syndrome. *Continuum (Minneapolis, Minn)*. 2017;23(5, Peripheral Nerve and Motor Neuron Disorders):1295-309.
- Thompson AJ, Banwell BL, Barkhof F, Carroll WM, Coetzee T, Comi G, et al. Diagnosis of multiple sclerosis: 2017 revisions of the McDonald criteria. *The Lancet Neurology*. 2018;17(2):162-73.
- Boussaid S, Rahmouni S, Rekek S, Jammali S, Cheour E, Sahli H, et al. Acute transverse myelitis revealing ankylosing spondylitis: A case report and literature review. *Clinical case reports*. 2021;9(10):e04878.
- Kunchok A, Aksamit AJ, Jr, Davis JM, III, Kantarci OH, Keegan BM, Pittock SJ, et al. Association Between Tumor Necrosis Factor Inhibitor Exposure and Inflammatory Central Nervous System Events. *JAMA Neurology*. 2020;77(8):937-46.
- Garcia S, Fernandes BM, Sousa JMM, Terroso G, Guimarães J, Abreu P, et al. Multiple Sclerosis in rheumatic patients treated with tumor necrosis factor alpha inhibitors: a single-center retrospective case series and literature review. *Acta reumatologica portuguesa*. 2021;46(3):266-71.
- HUMIRA (adalimumab) Abbott Laboratories. 2003 [access date: 11/02/2021]. Available from: https://www.accessdata.fda.gov/drugsatfda_docs/label/2002/adalabb123102lb.htm.
- Khan E, Shrestha AK, Colantonio MA, Liberio RN, Sriwastava S. Acute transverse myelitis following SARS-CoV-2 vaccination: a case report and review of literature. *J Neurol*. 2021:1-12.
- McLean P, Trefts L. Transverse myelitis 48 hours after the administration of an mRNA COVID 19 vaccine. *Neuroimmunology Reports*. 2021;1:100019.