

Therapy of calcinosis universalis complicating adult dermatomyositis

Georgina Terroso¹, Miguel Bernardes¹, Abelha Aleixo¹, Pedro Madureira¹,
Romana Vieira¹, Alexandra Bernardo¹, Lúcia Costa¹

ACTA REUMATOL PORT. 2013;38:44-48

ABSTRACT

Although frequent in juvenile dermatomyositis, calcinosis is a rare finding in adult dermatomyositis. It has been associated with disease activity and delayed treatment. It is more common in later phases of the disease, in sites under chronic stress and trauma. Calcinosis has been associated with inflammation but information about its pathogeny continues to evolve as we learn more about the underlying processes. Being uncommon, there is no standard therapy and management is guided by case studies and series. Different treatments have been used in an attempt to clear calcinosis lesions and prevent its recurrence but none has been clearly effective. The authors present the case of a 25-year-old female diagnosed with dermatomyositis who developed calcinosis universalis after stopping therapy. Immunosuppressive therapy was reinitiated and therapy aiming at reduction of calcinosis was sequentially tried using: colchicine, hydroxide magnesium, diltiazem, alendronate, probenecid and pamidronate. After receiving intravenous pamidronate, calcinosis lesions decreased and the patient regained full range of movement and quality of life. No recurrence has occurred after eight years of follow-up.

Keywords: Calcinosis universalis; Adult dermatomyositis; Treatment.

INTRODUCTION

Dermatomyositis is a systemic connective tissue disease of uncertain etiology characterized by an inflammatory myopathy and specific cutaneous abnormalities, including heliotrope rash of the eyelids, Gottron's papules over the knuckles, erythematous or urticarial patches of the trunk and calcinosis¹.

Calcinosis is a recognized feature of many connective tissue diseases, especially juvenile dermatomyositis (JDM) and systemic sclerosis.

Although commonly observed in JDM (in up to 40% of the patients), it is less frequent in the adult form, affecting only 10% of these patients^{2,3}.

Soft-tissue calcification can be classified in different subtypes: dystrophic, metastatic, idiopathic, iatrogenic, tumoral or, as more recently proposed, calciophylaxis³.

Dystrophic calcification is the most frequent type and it is the form associated with connective tissue diseases. It occurs as the result of tissue damage or changes in its structural components. In contrast to other subtypes, it occurs in the absence of abnormalities in serum calcium and phosphate levels³.

Calcinosis deposits develop in a mean of 3,4 years after the onset of the disease and result from the accumulation of hydroxyapatite with high mineral content after release of mitochondrial calcium by the damaged muscle². Bone proteins such as osteopontin, osteonectin and bone sialoprotein have also been identified in these deposits³.

It is more common in the late phases of the disease, in tissues which are under chronic stress, at sites of trauma, in more severe cases and in situations of delayed treatment^{3,4}.

Calcinosis has been associated with inflammation. Macrophages and pro-inflammatory cytokines such as IL-6, IL-1 and TNF α have been found in the calcium-rich fluid (calcium milk)³.

A genetic study showed that juvenile dermatomyositis patients with the TNF α -308AA allele, which is associated with higher TNF α production, were at higher risk of developing calcinosis as compared with patients with TNF α -308G³.

The normal calcium phosphate product in the extracellular compartment is near saturation. Under normal circumstances, tissue calcification is prevented by inhibitors of ectopic calcification such as matrix gamma-carboxyglutamic acid protein (MGP), a vitamin

1. Centro Hospitalar São João, Porto

K-dependent inhibitor of vascular calcification, and fetuin-A. Other proteins such as osteonectin act as promoters of calcification³.

A small study showed MGP expression in areas of muscle damage from patients with JDM, muscular dystrophy and inclusion body myositis versus occasional weak staining in normal controls^{3,6}. Marhaug *et al.* showed no difference in the levels of fetuin-A and osteopontin in JDM patients with or without calcinosis and controls. JDM patients with antibodies to p140, a 140-kd protein, have been found to have a particular high incidence of calcinosis³.

Calcinosis cutis concerns the deposition of calcium salt deposits in the skin and subcutaneous tissue. Calcinosis universalis, also known as dermal calcinosis or diffuse interstitial calcinosis, is characterized by the deposition of calcium in the skin, in the subcutaneous cellular tissue, and also in the tendons and muscles⁷.

The deposition of calcium in the skin, around joints and in the intermuscular fascial planes may cause more significant burden than myositis itself.

Calcinosis burden can result in pain, skin ulcerations expressing calcified material, secondary infection and joint contractures with severe functional disability preventing everyday life activities².

Delayed treatment and high disease activity are known risk factors for the development of cutaneous calcinosis. Inconsistent and/or low-efficacy treatments are predictive of the onset of calcinosis. Some authors have suggested that an early and aggressive treatment

regimen decreases the incidence of calcinosis⁸.

Being an uncommon condition, the understanding of the pathogenesis and treatment of calcinosis is still very limited. Management is essentially guided by case studies and series³. There is no standard therapy for calcinosis, although many agents have been used.

CLINICAL CASE

A 25-year-old female without relevant past medical history was referred to our centre with a 3 months history of progressive asthenia, weight loss, muscle ache and proximal muscle weakness.

Physical examination revealed an extensive poikiloderma lesion on the neck, Gottron's papules over the metacarpophalangeal joints and polyarthritis (proximal interphalangeal joints, wrists, knees). Muscle power of the upper and lower limbs was 4/5 proximally and 5/5 distally.

Laboratory blood tests demonstrated raised erythrocyte sedimentation rate (ESR), lactic dehydrogenase (LDH) and aldolase, without any other significant abnormalities including liver enzymes, CK, phosphorus, calcium, ANA and anti-Jo-1.

The electromyography of the upper and lower limbs didn't show myopathic patterns.

She was submitted to muscular and skin biopsy (left deltoid). The histology of the skin showed a discrete perivascular lymphoid infiltrate and slight hyperkera-

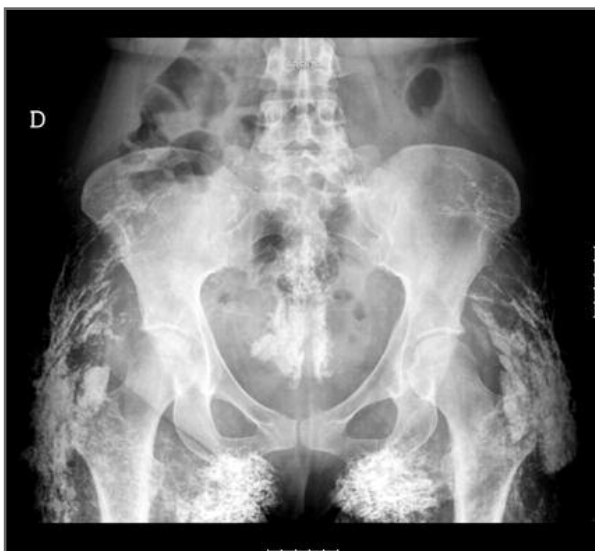

FIGURE 1. Extensive calcinosis lesions – hips

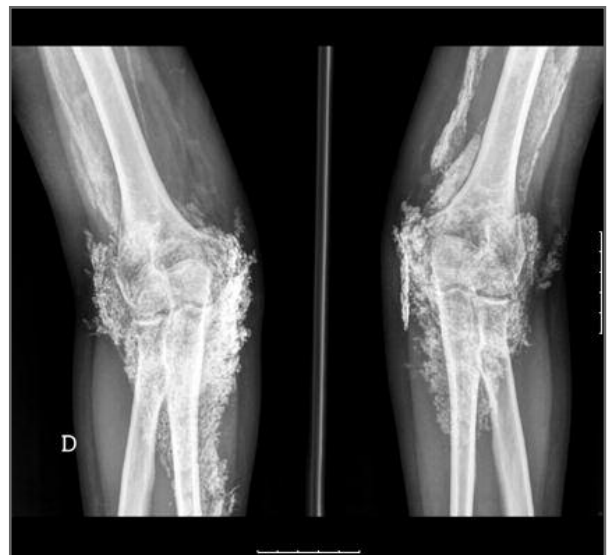

FIGURE 2. Extensive calcinosis lesions – elbows

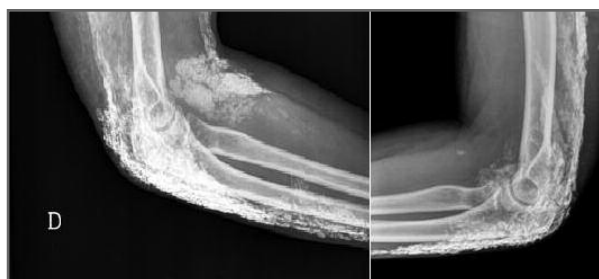


FIGURE 3. Extensive calcinosis lesions – right elbow

tosis. On the muscle, a focal lymphocytic infiltrate was found without evidence of necrosis.

Dermatomyositis was diagnosed according to Bohan and Peters criteria. The patient was sent home under oral prednisolone (1 mg/kg/day).

On clinical reevaluations performed every 2-3 months, she showed clinical improvement with a grade 5/5 on global muscle strength examination. Slow prednisolone tapering was performed and methotrexate (10 mg/ week) was added.

Eight months after the diagnosis was made, she complained of reduced mobility and informed us that she had stopped all medications two months before.

The X-rays showed extensive areas of calcinosis (Fig. 1-3): periarticular (on the elbows, hip and knees), intramuscular (gluteus and thighs) and subcutaneous. She had fixed flexion contractures of the knees and elbows.

Investigation didn't show any additional abnormalities in blood tests, including phosphorus and calcium levels.

Bone densitometry by dual-energy X-ray absorptiometry showed bone mineral density values compatible with osteopenia on the femur.

Given the disease severity and a familiar history of colon cancer, occult malignancy was screened. On total colonoscopy, a 3 cm polyp was removed. Histologic examination revealed an adenomatous polyp with a tubulovillous structure, low-grade dysplasia and focal areas of high-grade dysplasia. Microsatellite instability research on the lesion was negative.

Methotrexate was reintroduced in an increasing dose up to 25 mg/week. Colchicine 1 mg/ day and magnesium hydroxyde up to 900 mg daily were initiated.

Low dose therapy with warfarin was proposed, but the patient refused.

Given the lack of response and apparent progression of calcinosis under therapy, colchicine and magnesium hydroxyde were stopped. Diltiazem was started in an increasing dose (maximum tolerated dose: 240 mg/ day) as well as alendronate (70 mg/ week).

There was no clinical improvement and alendronate was withdrawn. Probenecid was then tried (maximum dose: 1500 mg/ day).

There was some improvement on elbow flexion but no significant change in the calcinosis lesions.

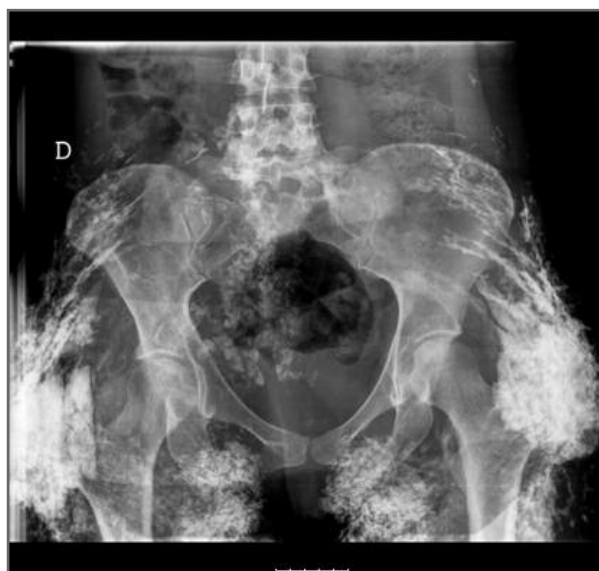

FIGURE 4. After 10 months of treatment with pamidronate – hips

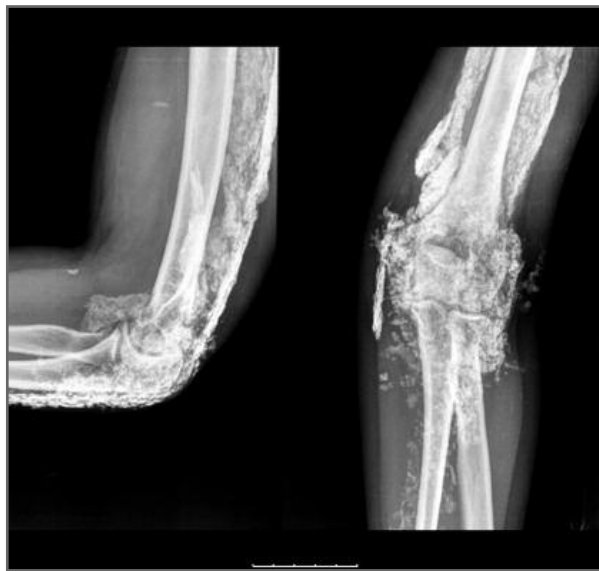

FIGURE 5. After 10 months of treatment with pamidronate – elbow

Pamidronate (60 mg monthly, corresponding to 1 mg/kg/ month) was started. Ten months afterwards (Fig. 4,5), the patient was able to cross her legs and tolerate squatting without discomfort.

She completed three years of therapy with pamidronate.

Since calcinosis was detected, several surgical drainages of the left elbow were required because of secondary infection.

During this time, her muscle disease activity remained in stable remission. Serum creatinine phosphokinase, aldolase, LDH and ESR remained in normal ranges.

After eight years, there was a small reduction in the lesions extension with total recovery of the range of movement and an improvement in quality of life. New calcinosis lesions did not occur.

DISCUSSION

Early aggressive treatment of disease activity remains the best method for calcinosis prevention, with no consistently effective or standard therapy currently available^{1,9}.

Treatment of established calcinosis is challenging since there are no controlled studies¹⁰.

Different drugs aimed at reducing calcinosis have been tried with variable results: colchicine, probenecid, aluminium hydroxide, diltiazem, intravenous immunoglobulin, bisphosphonates and anti-TNF α . No recommendations have been established due to the few patients evaluated and the unpredictable natural history of calcinosis with possible spontaneous remissions. Universal calcinosis seems less likely to resolve spontaneously¹⁰.

Colchicine has been reported to have beneficial effects in reducing calcinosis and to have no effect on calcinosis but rather on its associated secondary inflammation¹¹.

Aluminium hydroxide decreases the intestinal absorption of calcium phosphate, resulting in the reduction of the calcium phosphate plasma product¹. It lacks significant adverse effects but its effectiveness has not been demonstrated^{12,13}.

High levels of vitamin-K dependant MGP have been found at sites of calcinosis, and specially the carboxylated form acts as an inhibitor of calcinosis. Warfarin, a vitamin K antagonist, suppresses the carboxylation of MGP but still it has been tried in the management of calcinosis. Cuckierman *et al* reported impro-

vement in calcinosis in two of three systemic sclerosis patients treated with low-dose warfarin for 1 year¹⁴. However, Lassoued *et al.* followed up six patients (five with dermatomyositis, one with systemic sclerosis) treated with warfarin 1 mg/ day for one year and there was no improvement³.

Diltiazem has an inhibiting effect in the calcium channels of the cellular membrane. It may exert its effect by influencing intracellular calcium levels in macrophages³. In Balin *et al* s study, it was the most frequently medical therapy used for calcinosis¹¹. It can offer improvement in some DM cases^{1,2,3,12}.

Probenecid is a sulphonamide derivative that acts by increasing urinary phosphate excretion in the proximal renal tubule and lowering serum phosphorus. It has been used in some cases with increased serum phosphorus levels secondary to increased tubular reabsorption. However, it was effective in only a few patients^{12,15}.

Biphosphonates inhibit calcium turnover and can inhibit further calcium deposition to the already formed calcifications. They selectively destroy macrophages and inhibit their cytokine production^{3,10,16}.

The effect may not apply to all biphosphonates, since lack of efficacy of etidronate (a non-nitrogen-containing compound of lesser potency) has been reported¹⁷.

Marco Puche *et al* reported three cases of calcinosis in JDM treated with IV pamidronate 1 mg/ Kg/day on 3 consecutive days every 3 months. There was a significant decrease of calcinosis in all patients, with a total clearance in one patient^{3,12,18}. Slimani *et al.* reported a patient with JDM and extensive calcinosis who was first treated with colchicine without benefit followed by pamidronate 2 mg/Kg/year (15 mg every 3 months on the first year, 30 mg every 4 months on the second year), showing a dramatic improvement by 2 months and complete resolution by 2 years, without appearance of new calcifications during 5 years follow-up¹⁰.

Alendronate is an orally administered nitrogen-containing biphosphonate which as also been used to treat calcinosis in JDM with good results^{12,17}.

In comparison to alendronate, pamidronate has the advantage of its intravenous administration, preventing esophagitis and allowing greater compliance¹².

Incision and drainage have been used successfully as a local treatment³. Surgery may be considered for symptomatic pain relief and function improvement^{9,11}.

In contrast to JDM, calcinosis is a rare diagnosis in the adult form.

Our patient presented with calcinosis universalis following immunosuppressive therapy discontinuation. The aggressiveness of the condition justified the reintroduction of the disease-modifying antirheumatic drugs (DMARD) and the use of multiple drugs in an attempt to decrease her calcinosis deposits.

Colchicine, aluminium hydroxide, diltiazem, probenecid, alendronate and pamidronate were sequentially tried.

The best results were achieved with pamidronate. Ten months after beginning the treatment, she showed marked functional improvement and there was a radiographic decrease in the lesions.

After eight years of follow-up, she has totally recovered the range of movement with improvement in her quality of life and new calcifications have not been reported.

CORRESPONDENCE TO

Georgina Maria Ferreira de Oliveira Terroso
Serviço de Reumatologia - Hospital de S. João, EPE
Alameda Prof. Hernâni Monteiro
4200 PORTO, Portugal
E-mail: georteroso@gmail.com

REFERENCES

1. Ichiki Y, Akiyama T, Shimosawa N, Suzuki Y, Kondo N, Kitajima Y. An extremely severe case of cutaneous calcinosis with juvenile dermatomyositis, and successful treatment with diltiazem. *Br J Dermatol* 2001; 144:894-897.
2. Abdallah-Lotf M, Grasland A, Vinceneux P, Sigal-Grinberg M. Regression of calcinosis cutis with diltiazem in adult dermatomyositis. *Eur J Dermatol* 2005; 15:102-104.
3. Chander S, Gordon P. Soft tissue and subcutaneous calcification in connective tissue diseases. *Curr Opin Rheumatol* Published Online First 7 January 2012. doi:10.1097/BOR.0b013e32834ff5cd.
4. Rosa Neto NS, Goldenstein-Schainberg C. Juvenile dermatomyositis: review and update of the pathogenesis and treatment. *Rev Bras Rheumatol* 2010;50:299-312.
5. Miyamae T, Sano F, Ozawa R, Imagawa T, Inayama Y, Yokota S. Efficacy of thalidomide in a girl with inflammatory calcinosis, a severe complication of juvenile dermatomyositis. *Pediatr Rheumatol Online J* 2010;8:6.
6. van Summeren MJH, Spliet WGM, Royen-Kerkhof A, et al. Calcinosis in juvenile dermatomyositis: a possible role for the vitamin K-dependent protein matrix gla protein. *Rheumatology* 2008; 47: 267-271.
7. Santili C, Alkari M, Waisberg G, Kessler C, Alcantara T. Calcinosis universalis: a rare diagnosis. *J Pediatr Orthop B*. 2005; 14: 294-298.
8. Kavala M, Sudogan S, Can B, Zidanci I, Kuru I, Beyhan S, Kocaturk E. An extremely severe case of cutaneous calcinosis complicating adult dermatomyositis. *Clin Exp Dermatol* 2009;34:115-116.
9. Fleury J, Guillet G, Anyfantakis V, Huguier V. Unusual calcinosis of muscular loges in a 37 year old patient with a history of juvenile dermatomyositis. *Eur J Dermatol* 2010;20:647-648.
10. Slimani S, Abdessemed A, Haddouche A, Ladjouze-Rezig A. Complete resolution of universal calcinosis in a patient with juvenile dermatomyositis using pamidronate. *Joint Bone Spine* 2010; 77: 70-72.
11. Balin SJ, Wetter DA, Andersen LK, Davis MDP. Calcinosis cutis occurring in association with autoimmune connective tissue disease: The Mayo Clinic experience with 78 patients, 1996-2009. *Arch Dermatol* Published Online First 19 December 2011. doi:10.1001/archdermatol.2011.2052.
12. Marco Puche A, Calvo PI, Lopez MB. Effectiveness of treatment with intravenous pamidronate for calcinosis in juvenile dermatomyositis. *Clin Exp Rheumatol* 2010; 28: 135-140.
13. Nakagawa T, Takaiwa T. Calcinosis cutis in juvenile dermatomyositis responsive to aluminium hydroxide treatment. *J Dermatol* 1993; 20: 558-560.
14. Cukierman T, Elinav E, Korem M, Chajek-Shaul T. Low dose warfarin treatment for calcinosis in patients with systemic sclerosis. *Ann Rheum Dis* 2004; 63: 1341-1343.
15. Nakamura H, Kawakami A, Ida H, Ejima E, Origuchi T, Eguchi K. Efficacy of probenecid for a patient with juvenile dermatomyositis complicated with calcinosis. *J Rheumatol* 2006; 33: 1691-1693.
16. Boulman N, Slobodin G, Rozenbaum M, Rosner I. Calcinosis in rheumatic diseases. *Semin Arthritis Rheum* 2005; 34: 805-812.
17. Ambler GR, Chaitow J, Rogers M, McDonald DW, Ouvrier RA. Rapid improvement of calcinosis in juvenile dermatomyositis with alendronate therapy. *J Rheumatol* 2005;32:1837-1839.
18. Silverman SL. Biphosphonate use in conditions other than osteoporosis. *Ann N Y Acad Sci* 2011; 1218:33-37.

III CURSO BÁSICO DE ECOGRAFIA MÚSCULO-ESQUELÉTICA

Porto, Portugal
19 a 21 Abril 2013